

The Gerber Articulator and System of Full Denture Construction

Part 2(b)

Setting-up the Teeth and Finishing the Dentures

By G. E. White, Technical Instructor, University of Sheffield Dental School



The Gerber Articulator and System of Full Denture Construction

Taken from "The Dental Technician" 1973, Vol. 26 No. 4

The Gerber Articulator and System of Full Denture Construction

The sagittal condylar path angles obtained from the extra-oral tracings are transferred to the Condylator mechanism of the articulators. The stylus and tracing plates are removed from the blocks and new wax added to the rim of the upper occlusal block until it again makes contact with the lower rim. Crest of the ridgelines are drawn on each model, together with lower ridge profile lines, which are drawn on the sides of the model mounting plaster. The lowest point of this line is marked with a bisecting line. (Fig. 7.)

Gerber arranges teeth so that the forces of mastication applied to them are least able to dislodge the dentures. Gerber insists that the occlusal surfaces of the posterior teeth *must follow the curve of the lower ridge*. This simple rule ensures that occlusal forces are always at right angles to the ridge, so promoting a high degree of stability during function, when the dentures are held apart by hard food and the patient is applying strong closing pressure.

Setting-up commences with the upper anterior teeth, which are arranged to the usual appearance criteria. Setting-up of the posteriors begins with the first lower molar teeth, which are set over the "lowest" and, therefore, most stable part of the ridge. (Fig. 7.) The remainder of the lower posteriors are then set into place, taking the usual care to keep them over the crest of the ridge. If the profile of the lower ridge rises sharply as it approaches the retromolar pad, the teeth would have to be set on an inclined plane and forces applied to them would be resolved in a direction which would propel the lower denture in a forward direction (Fig. 9.) To avoid this the last molar tooth is omitted or replaced by a premolar to confine the posterior teeth to the most horizontal and,

therefore, most stable part of the ridge. This principle is similar to the way a *saddle is positioned on a horse's back*. (Fig. 8.) Many full lower dentures lack functional stability when the upper and lower teeth are separated and move forwards during masticatory pressure in the molar region of the dentures because this simple rule of confining artificial teeth to stable areas has not been observed. This propulsive movement causes sore spots under the lower denture and eventually leads to the destruction of the underlying alveolar bone. (Fig. 9.)

Gerber Condyliform posterior teeth are designed so that the palatal cusps only of the upper teeth fit into a fossa or hollow contained in each of the opposing lower teeth. (Fig. 10A.) The principle is similar to a mortar and pestle. (Fig. 10B.) They are wider bucco-lingually than most conventional posterior teeth and give better results because the bulge of the buccal surface makes a satisfactory contact with the cheek. If there is a cross bite relationship between the maxilla and mandible than the teeth are arranged so that the buccal rather than the palatal cusps of the upper teeth engage the fossae in the lower teeth. (Fig. 10C.)

As well as dictating the radius of the "Spee curve" and the number of posterior teeth to be used, the lower alveolar ridge can be assessed for its denture-supporting qualities to indicate the way the posterior teeth will occlude. (Fig. 11.)

After the upper anteriors and the upper and lower posteriors have been set up, lower anteriors are selected which will fill the gap between the left and right lower first premolar teeth. The lower incisors lie directly over the crest of the ridge. They may be tilted forwards a little which, together with a hollow in the denture base

Fig. 7. The left and right ridge profiles are drawn on the sides of the model mounting plaster. A mark bisects the line at the lowest and therefore most stable part of the ridge.

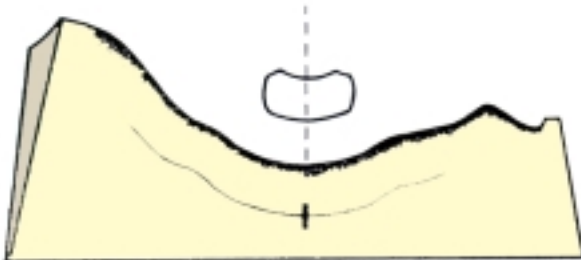


Fig. 8. Stability during mastication is improved if the lower teeth follow the curve of the lower ridge. This ensures that occlusal forces are always at right angles (90 degrees) to the surface of the alveolar process.

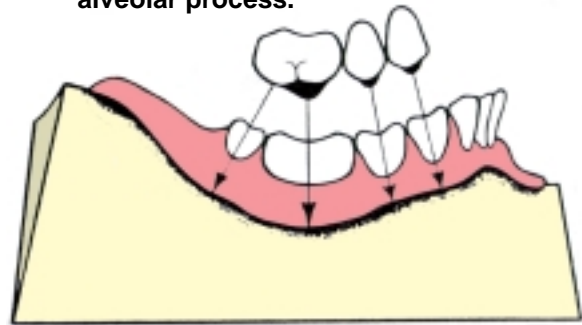
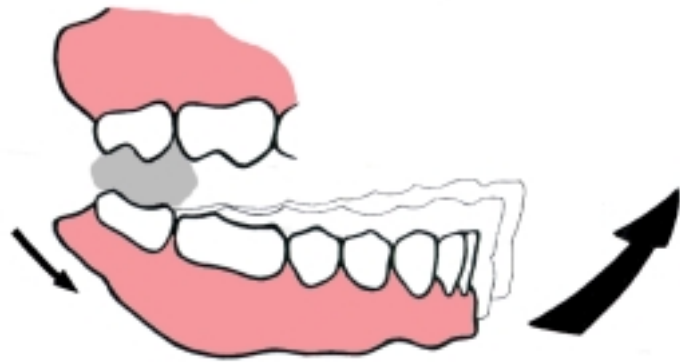

Fig. 9. If the molar teeth are set over a sloping part of the ridge the lower denture moves forward during mastication.



anteriorly, makes allowance for a contracting orbicularis oris muscle which might otherwise displace the denture backwards.

When the setting-up has been finished the teeth are checked for contact in centric occlusion in the following way. The locks controlling condylar movement on the Condylator are positioned to allow hinge movements only. Green typewriter ribbon (10 cm. Wide) is placed between the upper and lower teeth and the articulator closed. A proper fitting of the upper cusps into the lower fossae is shown by a green dot in the centre of each fossa. The dots should be over the alveolar ridge. (Fig. 12.)

The dentures are waxed to make them ready for try-in. In the mouth the dentures are assessed according to standard criteria for speech and appearance. The

stability of the dentures is tested by applying firm pressure with a pointed instrument on to the occlusal surfaces of any tooth, one side at a time. The dentures should not move. The dentist attends to the shape of the wax flanges at this time because a good deal of extra stability is to be gained if the shape of the flanges is in harmony with the movements of the lips and cheeks during function. When the try-in has been completed the dentures are sealed to their respective models and the models removed from the mounting plaster. The tapered sides of the models makes them come away easily and produces an accurate socket in the plaster into which the models can be accurately returned, carrying the processed dentures.

Processed dentures need to be returned to the articulator to remove the errors of occlusion produced by

volumetric changes in the denture base material during polymerisation and to grind-in the occlusal surfaces of the posterior teeth to produce what Gerber calls a "poly-valent" occlusion. (Fig. 13.) This means that although the basic mortar shape of the occlusal surfaces of the lower is retained, it has to be re-worked slightly so that its shape is in harmony with the articulator's reproduction of the patient's own particular temporomandibular joints movements. This is done as follows:

A. The locks controlling the articulator's

reproduction of condylar movement are positioned to allow hinge mandibular movements only. Green typewriter ribbon is used between the teeth to check that the cusp to fossa contacts developed during setting-up are still present. If due to processing errors a tooth does not show a satisfactory green dot, then the other teeth which do show evidence of contact with opposing teeth have their green dots ground away slightly with revolving 6 mm. spherical stones. This is continued until all the lower posterior teeth show a proper contact with the cusps of the upper teeth.

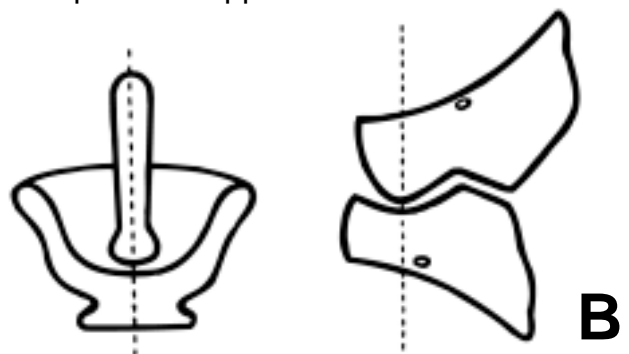
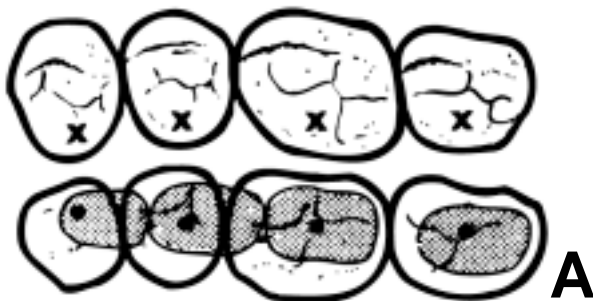

Fig.10. A. The palatal cusps of the upper posteriors (X) occlude in the central fossae of the lower teeth with a point contact. The teeth work together within the shaded areas. B. The principle is the mortar and pestle. C. With the cross bite the necks of the teeth are moved buccally to maintain cheek contact and buccal cusps engage the lower fossae.

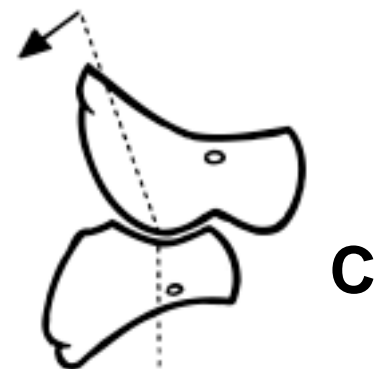


Fig. 11. A. Full anatomical occlusion-used only with good ridges. B. Reduced occlusion-upper teeth tilted to prevent buccal cusp contact. For average to poor ridges. C. Reduced occlusion-tooth tilted and buccal cusp ground away. For poor ridges. D. Mixed occlusion-all premolar lower posterior teeth set-up. For very poor ridges and to increase tongue space.

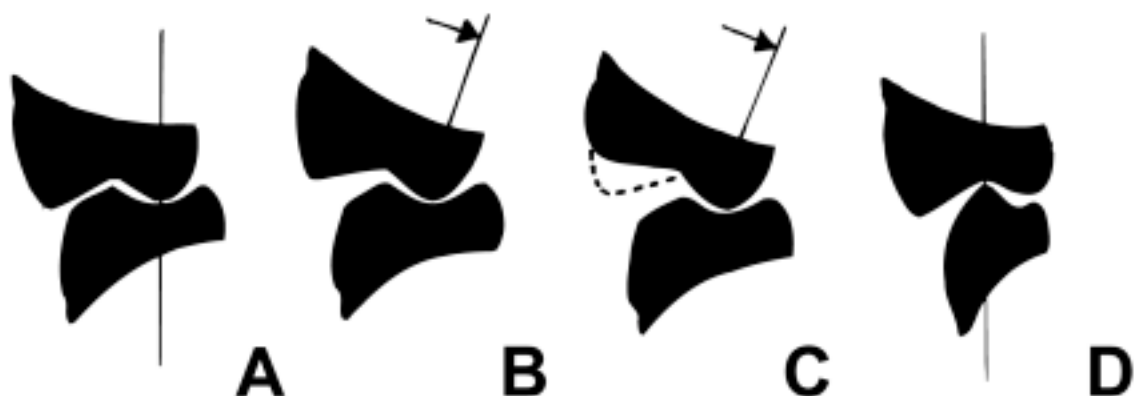
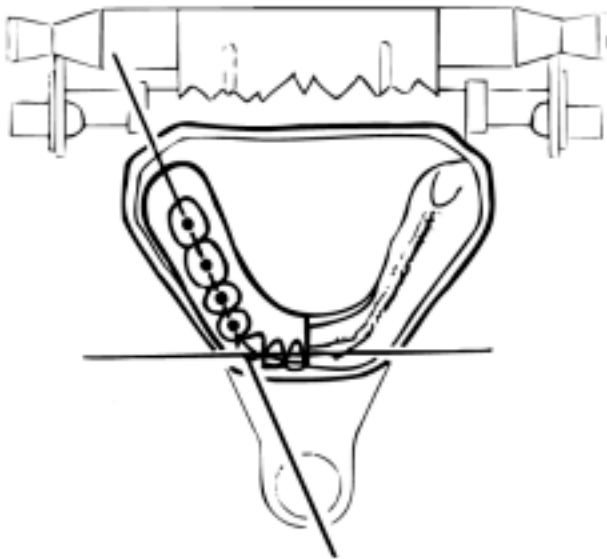


Fig. 12. A dot contact produced in the lower teeth by single upper cusp. The dots are over the crest of the ridge.

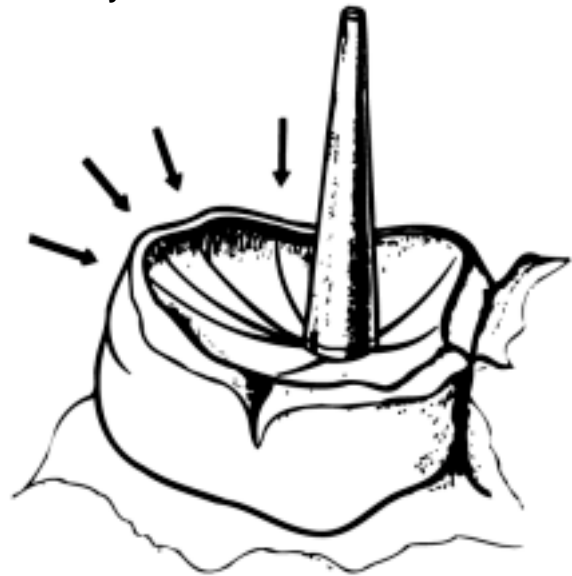

B. The vertical pin is raised so that it cannot make contact with the incisal guidance table and so cannot influence mandibular guidance.

C. The locks are now adjusted to allow protrusive, lateral and Bennett mandibular movements to be simulated by the articulator. **Red** typewriter ribbon is now used between the teeth, whilst the articulator is moving through all possible excursions. The red colour used after the green centric check now makes the original green centric dots look "black". These black dots show equilibrated centric and only the red marks in the fossae of the lower teeth, which show interference are lightly stoned away. This grinding is quickly done and harmonises the standard fossae shape of the Condyliform teeth with the patient's individual condylar guidance, radius of Spee curve and spatial position of the models within the frame of the articulator.

D. The locks are now adjusted so that a retral mandibular movement from centric is added to the protrusive, lateral and

Fig. 13. The "mortar and pestle" which allows smooth tooth movements in any direction.



Bennett envelope of movement and again high spots are ground away.

The smooth protrusive, lateral and retrusive articulation of the teeth which this tooth form and method of grinding produces is further refined by using a mixture of 220 grit carborundum and glycerine between the teeth and moving the articulator so that the teeth are ground together in a rotary manner, starting with very small movements and increasing these in size until a radius of about 3 mm. is reached. About 10 to 15 revolution in a clockwise direction followed by a similar number in an anti-clockwise direction usually suffices to refine and merge the ground and unground areas of the fossa into a single unified bowl shape in which the cusp from an upper tooth can move in any direction with equal facility. (Fig. 13.)

Now the dentures can be removed from the models and the resin "flash" and other sharp projections removed. The dentures are not polished but are straightaway tried in the patient's mouth so that the areas developed in wax to allow the musculature to stabilise the dentures can be finally shaped with cutting instruments

at the chair side. Particular attention is given to accommodating the buccinator and orbicularis oris muscles in both dentures and the lingual flange of the lower denture almost always terminates just beyond the mylohyoid ridge. The precise outline of the denture lingually is determined by the dentist, who must be able to raise the floor of the patient's mouth by finger pressure under the chin without displacing the denture.

A novel but revealing test of denture stability in the teeth apart situation is to invite the patient to bite hard on to a fairly hard object, say a pencil, which the patient holds in his hand and uses in different parts of the mouth, not neglecting the last molar teeth. If the teeth have been set to follow the curve of the lower ridge and do not go too high up a steeply sloping approach to the retromolar pad, the denture will not move, no matter if the ridges are well formed or flat. If the dentist follows the impression technique correctly, the dentures resist removal from the mouth almost regardless of the shape of the residual alveolar processes. When the dentist is satisfied with the retention and stability, the dentures are polished in the usual way. Very great care is taken not to polish within 2 mm. of the periphery, which is left quite undisturbed.

Conclusion and Summary

Patients who have worn full dentures for some time can present themselves for new dentures with mouths that have changed radically from the time the original dentures were fitted. Typically the upper alveolar processes are relatively unchanged while at the same time the lower alveolar processes show varying degrees of resorption up to the terminal flat lower ridge problem which can be so difficult to solve in older patients. This almost endemic pattern of alveolar bone loss is not a chance or random misfortune. Its origins can be traced in the majority of instances to dentures which

have what Fenn, Liddelow and Gimson (1961) call "plain line articulation" of the teeth, i.e. teeth set up without regard to lateral jaw movements. These dentures are destructive. They tend to move about in use because of cuspal interferences and cause pain and sore spots under the denture. If these traumatic forces exceed the physiological tolerance of the alveolar bone, it resorbs.

If the original fit of the dentures was good then bone resorption can be kept to a minimum if the patient can learn to avoid making lateral and protrusive movements and to chew with a simple hinge-like action. It is reasonable to assume that we can expect a small number of patients to learn these new masticatory movements perfectly and that this number will probably be balanced by those who will be unable to show any significant control over their dentures, even after long perseverance. This latter group complain that "the dentures do not work properly" or "they move and hurt when I eat". The pain they experience is usually lingual and the crest of the ridge and is produced by the "dragging" effect when the imbalanced teeth attempt to slide over each other during lateral and protrusive jaw movements. To the denture movements attributable to cuspal interference can be added the strong propulsive movement produced when the posterior teeth are set on an inclined part of the ridge. (Fig. 9.) The only structure, which can resist this movement, is the relatively delicate anterior segment of the lower alveolar bone and its thin covering of mucosal tissue. Forward lower denture movement elicits a quick response from the mucosa in the form of pain in the area of the lingual fraenae. Any attempt to ease the denture over these painful areas will only exacerbate the situation by spoiling the fit and retention of the denture.

With the exception of those who can change the way they eat to accommodate their dentures' occlusal disharmonies, the

remainder of patients will experience some denture movement during mastication which in most cases will encourage the underlying alveolar bone to resorb more rapidly than would be the case with stable dentures. The resorption reaches a point where the fit of the dentures is affected and allows the cuspal interferences to move easily dislodge the denture and so a circle of imbalance resorption more imbalance more resorption is established which can so quickly destroy the alveolar processes as effective foundations for dentures.

In order that teeth can be set up to avoid destructive cuspal interferences, it is essential to use an articulator which copies the movements of the mandible of the patient for whom the dentures are being made so that tooth contacts developed in the laboratory will be reproduced in the mouth. Gerber's research (1959) has drawn attention to the inadequacies of adjustable two axis articulators. They have their own individual movement characteristics and, in Gerber's opinion, are not able to generate the correct mandibular paths of movement on the working side (side to which the mandible moves in a lateral jaw movement).

Gerber has pointed out that balanced occlusion and balanced articulation do not necessarily provide denture stability if the teeth are set on an inclined alveolar bone foundation. The main objective of the Gerber system of full denture construction is to provide the patient with dentures which are stable and passive in use. Gerber does this by making sure that the occlusal surfaces of the teeth move in close harmony with each other and with the movements of the temporomandibular joints of which Gerber considers the Bennett movement constitutes a very important part. For many years technicians and dentists have questioned the validity of anatomical articulation on the grounds that it can only be effective as a stabilising influence when the teeth

are working together in contact, and when they are separated by food this influence will be lost at precisely the time it is most needed. With this in mind Gerber has been able to significantly extend stability into the tooth apart-dentures under load situation by limiting the posterior teeth to those more horizontal areas of the lower alveolar process which simple laws of mechanics indicates are the most suitable to receive pressure without denture movement and by arranging the occlusal surfaces parallel to the curve of the lower ridge. (Fig. 8.)

Although this method of setting-up means that the size of the occlusal table may be reduced in difficult cases, because Gerber contends that it is better to omit a tooth if it has to be placed where it would add to the instability of the denture, the denture base is always as large as intra-oral muscle activity will allow. Although Gerber uses other materials such as plaster of Paris when the ridges are flabby, the material most used by him is zinc oxide-eugenol paste, used in a close-fitting resin tray. One of the most important reasons for using the material in this way, apart from the mucosal adaptation to the alveolar bone it produces (Fig. 1) is that the combined thickness of tray and impression material is small and it is only by using such a technique that an accurate tray supported impression of the sulcus can be obtained. The dentist controls the shaping of the periphery of the impression by manipulating the soft tissues of the mouth so that only areas which move during normal function are accommodated in the impression. This technique, unlike some "functionally trimmed" impression techniques, does not rely on patients co-operation in making movements with the tongue which are not used in normal speech, mastication or swallowing.

The intra-oral Gothic arch tracing makes it possible for the dentist to obtain reliable records of the horizontal jaw relationship without the risk of mucosal

“compression” produced by uneven contact of the rims during the sealing together of the blocks. The Gothic arch tracing has the great advantage that the dentist can check that he has recorded a properly retruded condylar position before he dismisses the patient. Payne (1969) investigated the relationship between the apex of the intra-oral Gothic arch and the position of habitual closure in the edentulous person and found that:

1. Habitual closure occurs at a precisely defined position and does not occur over an area.
2. The actively traced apex point of a Gothic arch is a reliable guide to the position of habitual closure.
3. The apex point of an active Gothic arch tracing is not the most retruded position.

Gerber agrees with Payne that the apex point is a “muscular” position and not the most retruded or ligamentous condylar position in the glenoid fossae. In the Condylator articulator Gerber has allowed for an up to 2 mm. retrusive movement from the apex point (centric) to the fully retruded condylar position. It is not surprising perhaps that despite its advantages the Gothic arch has been neglected in this country when Payne, because of the lack of suitable apparatus, was obliged to construct his own stylus from the end of a ball point pen and a tracing plate from an acrylic disc carried in a cast metal framework. Gerber styli and plates are used in conventional occlusal blocks. The apparatus is reusable because the tracing is made at the correct vertical dimension and does not require the tracing plate to be perforated at the apex point to allow the stylus point to pass through as in the technique described by Fenn, Liddel and Gimson (1961).

The form of the condyloform posterior teeth establishes a mortar and pestle effect during mastication, which allows a smooth gliding tooth contact in any direction from centric occlusion. (Fig. 13.)

Condyloform teeth are made by Candulor in a range of shades to match their anterior teeth. They are available in resin and porcelain.

The central features of the Gerber system of full denture construction is the Condylator articulator. Gerber claims that it moves in a more natural manner because he has copied the shape of the condyle heads and the glenoid fossae and therefore the articulator can perform the Bennett movement more faithfully. The articulator and matching face bow are easy to use and duplicate in important respects the movements of the “fully adjustable” instruments such as the Grainger Gnathoscope and pantograph. The Condylator is a simple articulator which is capable of reproducing three dimensional condylar movement without conventional incisal guidance. The incisal guidance plate and rod are used only to maintain the vertical dimension during the setting-up of the teeth. The form of the setting-up can be “graded” so that it is able to follow the dictates of the shape of the lower alveolar processes. This provides denture stability even in unfavourably shaped alveolar processes.

Professor Gerber has developed a system of full denture construction which contains the best features of established techniques but in a form which he has brought up to date in the light of modern research and technology. The Condylator articulator and Condyloform teeth are unique to Gerber.

REFERENCES

- Craddock, F. W. (1949), J. Amer. Dent. Ass., 38, 6, 697-710.
Craddock, F. W. (1956) Prosthetic Dentistry, Kimpton.
Fenn, Liddel and Gimson (1961), Clinical Dental Prosthetics, Staples.
Fish, E. W. (1952), Principles of Full Dentures Prosthesis, Staples.
Gerber, A. (1959), Der Zahntechniker No. 6.

Payne, A. G, L. (1969), *Brit. Dent. J.*, 126,
5, 220-223.